

Effects of extracorporeal shock wave therapy on wounds of the distal portion of the limbs in horses

Dean D. Morgan, DVM; Scott McClure, DVM, PhD, DACVS; Michael J. Yaeger, DVM, PhD; Jim Schumacher, DVM, MS, DACVS; Richard B. Evans, PhD

Objective—To evaluate the effects of focused, extracorporeal shock wave therapy (ESWT) on the healing of wounds of the distal portion of the limbs in horses.

Design—Randomized controlled trial.

Animals—6 healthy adult horses.

Procedures—In each horse, a 4-cm-diameter full-thickness wound that included underlying periosteum was created on the dorsomedial aspect of each metacarpus and two 3-cm-diameter full-thickness wounds that included underlying periosteum were created on the dorsomedial aspect of each metatarsus. One randomly selected metacarpal wound and a randomly selected pair of metatarsal wounds were treated once weekly with ESWT at an energy flux density of 0.11 mJ/mm². For metacarpal wounds, swab specimens were collected for bacterial culture on days 1, 2, and 3 and area of epithelialization and extent of wound contraction were measured at 3- to 4-day intervals. Metatarsal wounds were biopsied after 2 and 4 weeks, and immunohistochemical staining for vascular endothelial growth factor, transforming growth factor- β 1, and insulin-like growth factor-1 was performed.

Results—Results of bacterial culture, area of epithelialization, and percentage of wound contraction did not differ between treated and untreated wounds; however, healing time for treated wounds (mean, 76 days) was significantly shorter than healing time for untreated wounds (90 days). Staining intensity of growth factors did not differ significantly between treated and untreated wounds.

Conclusions and Clinical Relevance—Findings suggested that ESWT may stimulate healing of wounds of the distal portion of the limbs in horses, although the mechanism by which healing was stimulated could not be identified. (*J Am Vet Med Assoc* 2009;234:1154–1161)

Primary closure of wounds of the distal portion of the limbs in horses is often impossible because of the relative lack of soft tissue and the immobility of surrounding skin.^{1,2} Such wounds therefore are typically allowed to heal by second intention, but healing by second intention can be complicated by formation of exuberant granulation tissue, which delays healing and results in a poor cosmetic outcome.^{3–5} Compared with wounds of the trunk, wounds of the distal portion of the limbs retract more, epithelialize more slowly, and cease to contract sooner.^{6,7}

Many drugs and devices have been advocated to increase the rate at which wounds of the distal portion of the limbs heal,^{3,5,6,8,9} but few controlled studies document the benefits of these products. Schumacher et al⁶ found no benefit of island grafting on the rates of epithelialization and contraction of surgically created

ABBREVIATIONS

ESWT	Extracorporeal shock wave therapy
IGF-1	Insulin-like growth factor-1
TGF- β 1	Transforming growth factor- β 1
VEGF	Vascular endothelial growth factor

wounds on the distal portion of the limbs of horses.⁶ Equine-derived amnion applied as a dressing to full-thickness wounds on the distal portion of the limbs of horses significantly sped epithelialization in 1 study,⁹ but this outcome could not be reproduced in another.¹⁰ Topical medications, including antimicrobials,³ corticosteroids,⁵ and various dressings,^{8–10} have shown little benefit to wound healing, although 1 study³ did demonstrate that application of 1% silver sulfadiazine cream resulted in a faster rate of epithelialization.

Extracorporeal shock wave therapy is a relatively new modality that has been shown to decrease time to healing of soft tissue injuries in many species.^{11–14} The mechanism by which ESWT increases the rate of wound healing is not currently known, although a consistent finding has been an increase in the expression of growth factors, including VEGF, TGF- β 1, and IGF-1, in treated tissue.^{13,15,16} Increased expression of these growth factors could result in an increase in neovascularization, which could in turn lead to faster wound healing.^{13,15–17}

From the Departments of Veterinary Clinical Sciences (Morgan, McClure), Veterinary Pathology (Yaeger), and Veterinary Diagnostic and Production Animal Medicine (Evans), College of Veterinary Medicine, Iowa State University, Ames, IA 50011; and the Department of Large Animal Clinical Sciences, College of Veterinary Medicine, University of Tennessee, Knoxville, TN 37996 (Schumacher). Dr. Evans' present address is Department of Veterinary Clinical Medicine, College of Veterinary Medicine, University of Illinois, Urbana, IL 61802.

Address correspondence to Dr. McClure.

In a study¹³ of the effects of ESWT on healing of partial-thickness wounds in pigs, researchers found that the effect of ESWT on the rate of epithelialization was dose related and that the maximum effect occurred following application of ten 14-kV pulses. Recently, survival of epigastric skin flaps in rats was shown to be enhanced by the application of ESWT,^{12,15} and in other studies,^{18,19} ESWT stimulated healing of skin flaps as much as did gene therapy with TGF- β 1 or VEGF. Finally, ESWT has been shown to decrease time to reepithelialization in human patients with deep partial-thickness burns.¹¹

Given the positive effects of ESWT on wound healing in other species, it seemed likely that it might be beneficial in horses also. The purpose of the study reported here was to evaluate the effects of focused ESWT on healing of surgically created wounds on the distal portion of the limbs in horses.

Materials and Methods

Animals—Six horses between 2 and 6 years old in which the metacarpal and metatarsal regions were visibly and palpably normal were used in the study. Horses were maintained in stalls throughout the experiment and fed grass and alfalfa hay ad libitum and 1.5 kg (3.3 lb) of a 12% grain mixture twice daily. The study protocol was approved by the Iowa State University's Animal Care and Use Committee.

Wound creation—In all horses, a 5-cm-diameter circle with 1-cm-long horizontal lines at the most medial and lateral aspects was tattooed on the dorsomedial aspect of the midmetacarpal region of each forelimb 4 weeks prior to the start of the study. On the first day of the study (ie, day 0), horses were sedated with xylazine (1 mg/kg [0.45 mg/lb], IV) and anesthetized with ketamine (2.2 mg/kg [1 mg/lb], IV), and a 4-cm-diameter circular full-thickness wound that included skin, subcutis, and underlying periosteum was surgically created in the center of each tattoo. At the same time, two 3-cm-diameter full-thickness wounds that included skin, subcutis, and periosteum were surgically created on the dorsomedial aspect of each metatarsus, with 1 wound 4 cm proximal and the other wound 4 cm distal to the middle of the metatarsus. All wounds were created with sterile templates.

Wounds were covered with a sterile, nonadherent dressing^a that was secured with conforming, rolled gauze.^b An absorbent cotton pad^c was then applied and secured with elastic rolled gauze^d and elastic tape.^e Horses were treated with phenylbutazone (4.4 mg/kg [2 mg/lb], IV) once before surgery and once daily for 3 days after surgery. Bandages were changed daily for the first 3 days after surgery and then at 3- to 4-day intervals until wounds were healed.

Experimental treatment—On day 1, a randomly selected metacarpal wound and a pair of randomly selected metatarsal wounds (ie, both wounds on 1 limb) were treated with ESWT. Wounds were covered with ultrasound coupling gel prior to ESWT, and ESWT was performed with a commercial unit.^f Metacarpal wounds received 500 pulses at an energy flux density of 0.11 mJ/mm². Both metatarsal wounds received 280 pulses at the same energy flux density, which resulted in an equal number of pulses per square centimeter of wound

area as was administered to the metacarpal wounds. Extracorporeal shock wave therapy was repeated weekly until the wounds were healed; all treatments were administered by an individual who was not involved in assessing wound healing. To help maintain blinding of observers involved in assessing wound healing, untreated control wounds were covered with ultrasound coupling gel each time ESWT was performed.

Assessment of wound healing—Metacarpal wounds were used to compare extent of bacterial contamination, granulation tissue formation, epithelialization, and wound contraction between treated and untreated control wounds. In addition, degree of limb swelling was compared between treated and untreated limbs, and radiography was performed to identify any osseous sequestration and the extent of any bone lysis or proliferation.

On days 1 (prior to ESWT), 2, and 3, swab specimens were obtained from each metacarpal wound by rolling a sterile swab over a 1-cm-long region in the center of each wound. Swabs were rinsed in 2 mL of sterile physiologic saline (0.9% NaCl) solution, and the resulting solution was submitted for quantitative bacterial culture, as described.²⁰ Bacterial isolates were subcultured, to ensure that a pure growth had been obtained, and tested in-house by means of conventional biochemical methods²⁰ to determine their identity.

During each bandage change, wounds were cleaned with physiologic saline solution and a digital photograph was obtained. Rulers were positioned vertically and horizontally close to the wound to serve as reference markers in the photographs. All wound measurements were obtained by a single individual (DDM), who was blinded to which wounds were treated.

Swelling of the limb was determined by measuring the circumference of the limb at the level of the horizontal tattoo marks that marked the center of the wound. Swelling was expressed as a percentage by dividing measured circumference of the limb by circumference prior to wound creation (ie, circumference on day 0) and multiplying by 100.

Quantity of granulation tissue was then scored on a scale from 0 to 3, where 0 = no granulation tissue, 1 = granulation tissue \leq 5 mm in depth and \leq 1 cm² in area, 2 = granulation tissue \leq 5 mm in depth that covered the entire area of the wound, and 3 = granulation tissue $>$ 5 mm in depth. The treated and control wound data were compared at each time point, and the sums of the scores for quantity of granulation tissue were compared for each healed wound.

Digital photographs were analyzed with image analysis software^g to determine the area within the tattoo, the area of epithelialization (ie, area of newly formed epithelium), and the area of the wound that remained (ie, that portion of the wound that was not epithelialized). Methods were similar to those described previously.⁷ Extent of wound contraction was calculated by subtracting the area within the tattoo from the largest area within the tattoo that was recorded (ie, area within the tattoo after the wound had enlarged to its maximum extent) and dividing by the largest area of the wound that was recorded (ie, area of the wound after the wound had enlarged to its maximum extent).

Dorsolateral-palmaromedial (30° lateral to the dorsopalmar line) radiographic projections of both meta-

carpal regions, centered on the wounds, were obtained on days 14, 28, and 42. Area of bone lysis and area of bone proliferation, if present, were determined by tracing the lytic or proliferative area on each image with image analysis software.⁸

Evaluation of histologic and immunohistochemical effects—Metatarsal wounds were used to compare histologic changes and expression of growth factors VEGF, TGF- β 1, and IGF-1 between treated and untreated control wounds. On day 14, a full-thickness rectangular excisional biopsy specimen spanning the full width of the wound was obtained from each distal metatarsal wound, and on day 28, a full-thickness rectangular excisional biopsy specimen spanning the full width of the wound was obtained from each proximal metatarsal wound. Each biopsy specimen was approximately 6 mm wide and incorporated adjacent grossly normal tissue on the medial and lateral aspects of the wound. For collection of biopsy specimens, horses were sedated with detomidine (20 μ g/kg [9.07 μ g/lb], IV) and restrained in stocks; 2% mepivacaine hydrochloride was injected circumferentially around the limb, proximal to the wound, prior to collection of biopsy specimens.

Biopsy specimens were placed in neutral-buffered 10% formalin for 24 hours and then in 70% isopropyl alcohol. Specimens were embedded in paraffin, and 5- μ m-thick sections were cut and stained with H&E or prepared for immunohistochemical staining.

Histologic examination of biopsy specimens—Biopsy specimens obtained on days 14 and 28 were examined, and depth of the surface exudate, depth of visible hemorrhage and loose granulation tissue, and depth of dense connective tissue were calculated by averaging measurements obtained for five 400X fields across the width of the specimen. Density of neutrophils in the superficial granulation tissue was scored from 0 to 3 by counting total numbers of neutrophils in five 400X fields of the superficial granulation tissue and calculating the mean value. Neutrophil score was then recorded as 0 if no neutrophils were identified in any of the 5 fields, as 1 if 1 to 10 neutrophils were identified/field, as 2 if 11 to 50 neutrophils were identified/field, and as 3 if > 50 neutrophils were identified/field.

Immunohistochemical staining of biopsy specimens—Sections for immunohistochemical staining were heated for 30 minutes at 57°C, and paraffin was removed by immersion in xylene for 5 minutes. Sections were then immersed in 100%, 95%, and 70% ethyl alcohol for 3 minutes each and then in distilled water for 3 minutes. Sections to be used for TGF- β 1 staining were steamed for 20 minutes in antigen retrieval solution^h; all sections were then treated for 20 minutes in a solution consisting of 10% normal goat serum, Tris, and bovine serum albumin in phosphate-buffered saline solution.

Antibodies used for immunohistochemical staining included antibodies against IGF-1, VEGF, and TGF- β 1.¹ Antibodies were diluted 1:10 (IGF-1) or 1:50 (VEGF and TGF- β 1) in a solution of Tris and bovine serum albumin in phosphate-buffered saline solution. For detection of IGF-1, a polyclonal IGF-1 antibody against human IGF-1 (NP_00609) that shared 100% homology with antibody against equine IGF-1 (NP_001075968) was used. For detection of VEGF, a VEGF antibody against human VEGF

(Q9GKR0.1) that shared 75% homology with antibody against equine VEGF (NP_001075290.1) was used; this VEGF antibody has previously been shown to be useful for detection of VEGF in samples from horses.^{21,22} For detection of TGF- β 1, a TGF- β 1 antibody validated by the manufacturer for use with equine samples was used.

Sections were bathed in solutions containing the primary antibody for 2 hours at room temperature and then rinsed with phosphate-buffered saline solution. Endogenous peroxidase activity was inhibited by applying 3% H₂O₂ for 10 minutes, and sections were then rinsed with phosphate-buffered saline solution. For detection of IGF-1 and VEGF, a multilink, goat anti-immunoglobulin secondary antibodyⁱ diluted 1:80 in Tris and bovine serum albumin in phosphate-buffered saline solution was subsequently applied, and sections were incubated for 15 minutes at room temperature and then rinsed in phosphate-buffered saline solution. For detection of TGF- β 1, a goat anti-rabbit secondary antibody^k diluted 1:500 in Tris and bovine serum albumin in phosphate-buffered saline solution was applied, and sections were incubated for 15 minutes at room temperature and then rinsed in phosphate-buffered saline solution.

Horseradish peroxidase streptavidin^l diluted 1:200 in Tris and bovine serum albumin in phosphate-buffered saline solution was applied to all sections for 15 minutes, and sections were rinsed with phosphate-buffered saline solution. All sections were stained with nova red^m for 5 minutes, rinsed with distilled water, counterstained with quarter-strength Shandon hematoxylin for 2 minutes, and again rinsed with distilled water. Sections were dehydrated through graded concentrations of ethyl alcohol and xylene, covered with glass coverslips, and allowed to air dry.

For negative control sections, phosphate-buffered saline solution was used instead of the primary antibody solution. Sections of healthy equine pancreas were used as positive controls for detection of IGF-1, and sections of equine skin with an extensive focus of granulation tissue were used as positive controls for detection of VEGF and TGF- β 1.

For each biopsy specimen, 5 randomly chosen 600X fields of immature, loose, granulating fibrous connective tissue were examined for intensity of cytoplasmic staining and number of cells positive for staining. A staining intensity score from 1 to 3 was assigned on the basis of mean number of positively staining cells per 600X field, with a score of 1 assigned if staining was detected in < 15 cells/600X field, a score of 2 assigned if staining was detected in 15 to 40 cells/600X field, and a score of 3 assigned if staining was detected in > 40 cells/600X field.

Data analysis—Multivariate ANCOVA was used to compare values for continuous variables between treated and control wounds for number of bacterial organisms cultured, limb swelling, bone proliferation, and bone lysis. The Cox proportional hazard model was used to compare granulation tissue scores between treated and control wounds at each time point during the study. Paired *t* tests were used to compare values for the sum of granulation tissue scores, depth of surface exudate, depth of visible hemorrhage and loose granulation tissue, neutrophil score, and depth of dense connective tissue obtained on days 14 and 28 between treated and control wounds and to compare values obtained on day 28 with values obtained on

day 14. A sign test was used to compare staining intensity scores for VEGF, IGF-1, and TGF- β 1 between treated and control limbs on days 14 and 28 and between day 14 and day 28. Kaplan-Meier survival analysis was used to compare healing time between treated and control wounds. A matched-pairs *t* test was used to compare the wound area, area of epithelialization, and percentage of contraction between treated and control wounds at each time point. All analyses were performed with standard software.^a Values of $P \leq 0.05$ were considered significant.

Results

Results of bacterial culture—Bacterial species isolated from treated and control metacarpal wounds were similar, with the most commonly isolated bacterial species being *Streptococcus equisimilis* and *Streptococcus equi* subsp. *zooepidemicus*. Other isolates obtained from multiple horses included α -hemolytic *Streptococcus* spp, coagulase-negative *Staphylococcus* spp, and *Staphylococcus aureus*. Total number of organisms obtained from swab specimens did not differ significantly between treated and control wounds on days 1 (mean [range] total number of organisms, 3.3×10^5 [0 to 2×10^6] vs 868 [0 to 3,920], respectively; $P = 0.36$), 2 (2.6×10^6 [0 to 6×10^6] vs 5.9×10^6 [0 to 3.4×10^6]; $P = 0.61$), or 3 (4.4×10^6 [3,200 to 6.4×10^6] vs 5.9×10^6 [0 to 2.3×10^6]; $P = 0.66$).

Degree of limb swelling—Circumference of the limb at the level of the metacarpal wound, expressed as a percentage of the initial circumference of the limb, did not differ significantly ($P = 0.99$) between treated and control limbs during the study period. At the time wounds were fully healed, mean \pm SD circumference of the limb at the level of the wound, expressed as a percentage of initial limb circumference, was $103.1 \pm 1.7\%$ for the treated limbs and $103.1 \pm 2.5\%$ for the control limbs.

Granulation tissue—Granulation tissue scores were not significantly different between treated and control metacarpal wounds at any time during the study. Sum of the granulation tissue scores assigned from the time of wound creation to the time of wound healing also did not differ significantly ($P = 0.56$) between treated and control wounds. Median total granulation tissue score was 7.5 (range, 2 to 16) for treated wounds and 5 (range, 3 to 32) for control wounds.

Epithelialization and contraction—Mean time for complete wound healing was significantly ($P = 0.05$) shorter for the treated metacarpal wounds (mean \pm SD, $75.8 \pm$

14.3 days) than for the control metacarpal wounds (90.3 ± 19.6 days). However, wound area differed significantly between treated and control wounds only on days 27, 31, 34, and 37 (Figure 1), area of epithelialization dif-

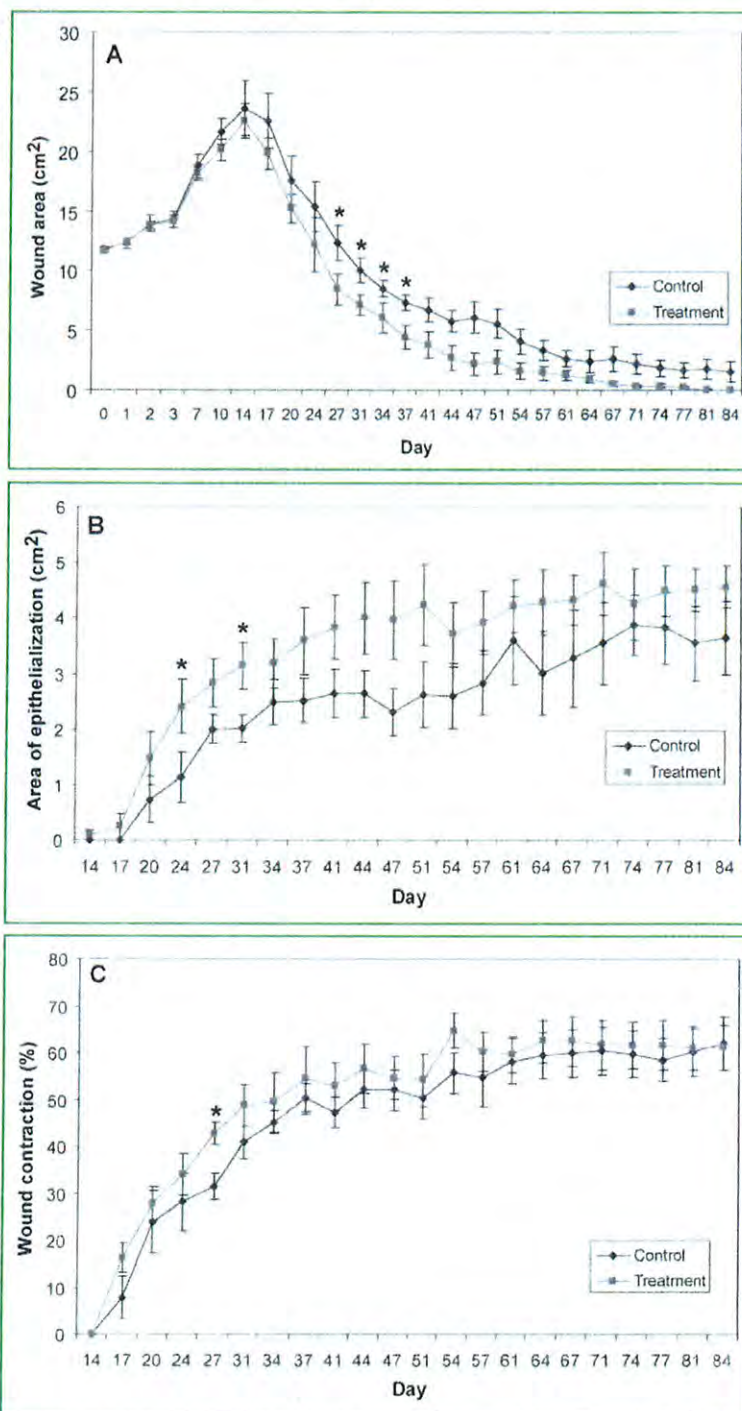


Figure 1—Mean wound area (A), area of epithelialization (B), and extent of wound contraction (C) for 6 healthy horses in which 4-cm-diameter full-thickness wounds were created on the dorsomedial aspect of the metacarpus bilaterally. Beginning on day 1, 1 wound in each horse was treated weekly with ESWT until the wound had healed and the other was maintained as an untreated control. For wounds that healed prior to the end of the study period (ie, day 84), values obtained on the day the wound was healed were carried forward. Error bars represent SE. *Values were significantly ($P \leq 0.05$) different between groups.

ferred between treated and control wounds only on days 24 and 31, and extent of wound contraction differed between treated and control wounds only on day 27. At the time wounds were completely healed, mean \pm SD area of epithelialization was 4.5 ± 0.92 cm² for treated wounds and 3.9 ± 1.5 cm² for control wounds ($P = 0.48$), and mean \pm SD extent of contraction was $61.3 \pm 11.8\%$ for treated wounds and $61.0 \pm 12.9\%$ for control wounds ($P = 0.96$).

Extent of bone lysis and proliferation—Mean area of bone lysis on dorsolateral-palmaromedial radiographic projections of the metacarpus did not differ between treated and control limbs on days 14 (mean \pm SD, 0.32 ± 0.21 cm² vs 0.27 ± 0.24 cm²; $P = 0.53$), 28 (0.09 ± 0.11 cm² vs 0.11 ± 0.22 cm²; $P = 0.81$), or 56 (0 ± 0 cm² vs 0.04 ± 0.09 cm²; $P = 0.36$). Similarly, mean area of bone proliferation on dorsoventral radiographic projections of the metacarpus did not differ between treated and control limbs on days 14 (mean \pm SD, 0 ± 0 cm² vs 0 ± 0 cm²; $P > 0.99$), 28 (0.48 ± 0.26 cm² vs 0.71 ± 0.62 cm²; $P = 0.18$), or 56 (0.31 ± 0.37 cm² vs 0.47 ± 0.37 cm²; $P = 0.22$).

Histologic findings—For biopsy specimens obtained on day 14 from the metatarsal wounds, depth of the surface exudate ($P = 0.07$), depth of visible hemorrhage and loose granulation tissue ($P = 0.42$), and neutrophil score ($P = 0.36$) did not differ significantly between treated and control wounds, and there was no dense connective tissue present in any wounds. Similarly, for biopsy specimens obtained on day 28 from the metatarsal wounds, there was no surface exudate in any wounds, and the depth of visible hemorrhage and loose granulation tissue ($P = 0.38$), neutrophil score ($P = 0.45$), and depth of dense connective tissue ($P = 0.23$) did not differ significantly between treated and control wounds.

Immunohistochemical findings—In general, examination of biopsy specimens following immunohistochemical staining revealed staining for IGF-1 in the cytoplasm of macrophages, fibroblasts, neutrophils, and immature endothelial cells (Figure 2); staining for TGF- β 1 in fibrinous exudate and in the cytoplasm of macrophages, fibroblasts, and endothelial cells (Figure 3); and staining for VEGF in the cytoplasm of fibroblasts, endothelial cells, macrophages, and smooth muscle cells (Figure 4). Intensity of staining varied within individual sections, with more intense staining in those sections composed of immature, loose, granulating fibrous connective tissue.

For biopsy specimens obtained on day 14, scores for intensity of staining for VEGF ($P > 0.99$), IGF-1 ($P > 0.99$), and TGF- β 1 ($P > 0.99$) did not differ significantly between treated and control wounds. Similarly, for biopsy specimens obtained on day 28, scores for intensity of staining for VEGF ($P = 0.37$), IGF-1 ($P = 0.31$), and TGF- β 1 ($P = 0.37$) did not differ significantly be-

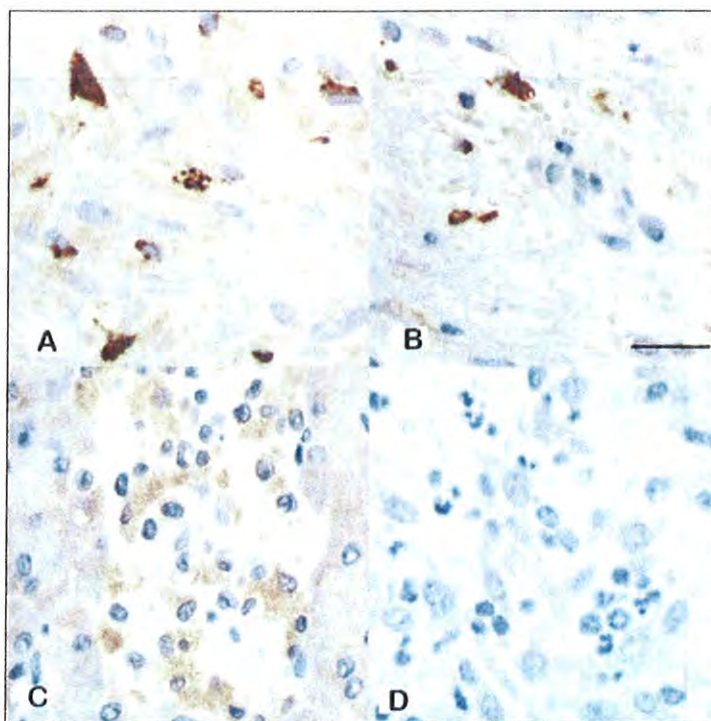


Figure 2—Photomicrographs of portions of wounds on the dorsomedial surface of the metatarsus in 2 horses that were treated by means of conventional bandaging alone for 14 days (A) or by means of bandaging in conjunction with weekly ESWT for 28 days (B). Sections have undergone immunohistochemical staining with antibodies against IGF-1. Compare the intensity of staining with intensity of staining in positive (C; healthy equine pancreas) and negative (D; equine skin with an extensive focus of granulation tissue for which saline [0.9% NaCl] solution was substituted for the primary antibody) control specimens. Shandon hematoxylin counterstain; bar = 25 μ m.

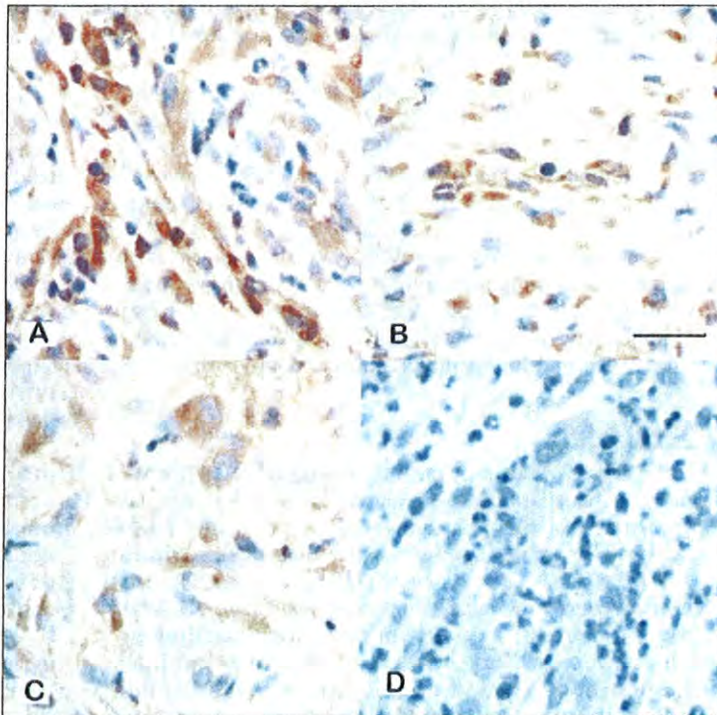


Figure 3—Photomicrographs of portions of wounds on the dorsomedial surface of the metatarsus in 2 horses that were treated by means of conventional bandaging alone for 14 (A) or 28 (B) days. Sections have undergone immunohistochemical staining with antibodies against TGF- β 1. Compare the intensity of staining with intensity of staining in positive (C; healthy equine pancreas) and negative (D; equine skin with an extensive focus of granulation tissue for which saline solution was substituted for the primary antibody) control specimens. Shandon hematoxylin counterstain; bar = 25 μ m.

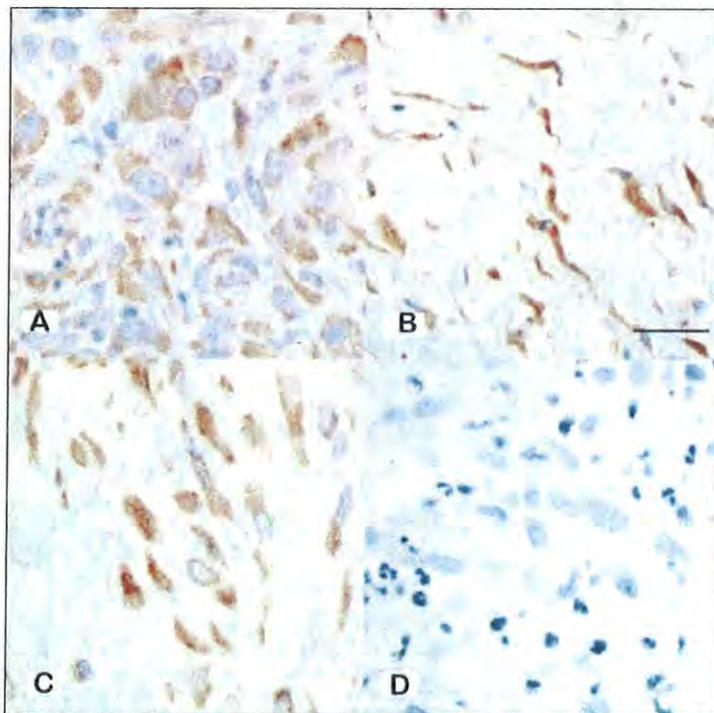


Figure 4—Photomicrographs of portions of wounds on the dorsomedial surface of the metatarsus in 2 horses that were treated by means of conventional bandaging alone for 14 days (A) or by means of bandaging in conjunction with weekly ESWT for 28 days (B). Sections have undergone immunohistochemical staining with antibodies against VEGF. Compare the intensity of staining with intensity of staining in positive (C; healthy equine pancreas) and negative (D; equine skin with an extensive focus of granulation tissue for which saline solution was substituted for the primary antibody) control specimens. Shandon hematoxylin counterstain; bar = 25 μ m.

tween treated and control wounds. For control wounds, intensity of staining for VEGF ($P = 0.03$), IGF-1 ($P = 0.015$), and TGF- β 1 ($P = 0.015$) was significantly lower for specimens obtained on day 28 than for specimens obtained on day 14. In contrast, for treated wounds, intensity of staining for VEGF ($P = 0.06$) and IGF-1 ($P = 0.25$) in specimens obtained on day 14 was not significantly different from intensity of staining in specimens obtained on day 28, although intensity of staining for TGF- β 1 was significantly ($P = 0.015$) lower for specimens obtained on day 28 than for specimens obtained on day 14.

Discussion

Results of the present study suggested that ESWT may decrease the healing time of wounds of the distal portion of the limbs in horses, in that mean healing time for treated wounds in the present study (mean \pm SD, 75.8 ± 14.3 days) was significantly shorter than healing time for untreated control wounds (90.3 ± 19.6 days). However, the mechanism by which healing was stimulated could not be identified, as area of epithelialization and extent of wound contraction did not differ significantly between treated and control wounds, except on a few days during the early healing period.

Although previous studies have examined the effect of ESWT on various tissues, the mechanism by which shock waves speed healing remains unknown. Several studies^{11,12} have shown that ESWT increases concentra-

tions of growth factors, including VEGF and TGF- β 1. In the present study, we did not identify any differences in expression of VEGF, IGF-1, or TGF- β 1 between treated and untreated control wounds. However, this lack of differences may have been due in part to the timing of when specimens were collected. In a previous study²³ involving horses, TGF- β 1 was shown to be most abundant during the inflammatory phase of wound healing, reaching peak concentration 24 hours after wounding, although expression was high throughout the 14-day study period. In the present study, growth factor expression was evaluated 14 and 28 days after wound creation, which may have been after differences would have been seen. Importantly, growth factor expression decreased between day 14 and day 28 in the untreated control wounds, as was expected.^{23,24} In contrast, expression of VEGF and IGF-1 did not decrease between day 14 and day 28 in the treated wounds, which suggested that ESWT may have caused expression of these growth factors to be maintained beyond the initial inflammatory phase of wound healing.

Other possible mechanisms by which ESWT could stimulate wound healing that have been proposed include stimulation of oxygen-derived free radicals, including superoxide and nitric oxide,^{25,26} and increased production of endothelial nitric oxide synthase.¹³ We did not attempt to study these mechanisms in the present study.

In the present study, we attempted to create wounds that would mimic, as closely as possible, naturally occurring traumatic lesions of the distal portion of the limbs in horses. Wounds were bandaged until they had completely healed, even though studies^{27,28} have shown that bandaging may lead to formation of excessive granulation tissue, because this was the standard treatment for such wounds in our hospital at the time of the study. The possibility of exuberant granulation tissue formation in response to ESWT was a concern, given results of previous studies that have shown that ESWT increases neovascularization,^{16,19} fibroblastic activity,²⁹ and expression of TGF- β 1,³⁰ all of which have been shown to be integral to the proliferative phase of wound healing⁵ and the development of exuberant granulation tissue.²⁸ However, excessive granulation tissue was not a problem in the present study. Importantly, we chose to use a nonadherent dressing throughout the study to prevent mechanical disruption of the wounds, and use of this nonadherent dressing may have helped prevent formation of exuberant granulation tissue in both treated and control wounds.³¹

We did not attempt in the present study to examine the effect of number of pulses or pulse energy on wound healing. Studies^{12,15,18,19} of survival of epigastric skin flaps in rats found that various ESWT protocols produced similar results, and a recent study⁶ found that as few as 1.4 pulses/cm² may be effective. It is possible that similar results were seen with previous protocols because all exceeded the minimum dose required for a response.

We elected to remove the underlying periosteum when creating wounds in the present study to mimic the situation for most naturally occurring wounds and evaluated the wound region radiographically to determine whether sequestra developed or periosteal new bone formed. We did not identify any reactive bony changes at the site of the wounds in the present study and, similar to results of a previous study,⁷ did not identify any instances of bone sequestration, perhaps because bone sequestration occurs only when the bone is infected.³² The sterile manner in which the wounds were created and the protection of the wounds with a sterile bandage may have prevented bone infection in the present study. In contrast, horses with naturally occurring wounds on the distal portion of the limbs may be more likely to develop bone sequestration because there is likely to be a long period from time of injury to initiation of treatment and because such wounds quickly become contaminated with manure and dirt.

In the present study, swab specimens obtained during the early treatment period were submitted for bacterial culture to determine whether ESWT delayed bacterial colonization of the wounds. An antibacterial effect of ESWT has been demonstrated in vitro at a high energy flux density (0.59 mJ/mm²) with over 1,000 pulses,³³ but whether ESWT has antibacterial effects in vivo, especially with the lower energy flux density and lower number of pulses used in the present study, is not known. Importantly, wounds in the present study were clean when treatment was initiated, and infected wounds may respond differently.

Only fresh, clean wounds were evaluated in the present study, and the effects of ESWT on contaminated and chronic wounds will need to be investigated. Additional study is also needed to identify the best times to perform ESWT and the best protocol to be used and to determine whether ESWT would be synergistic with other wound therapies, such as topical application of platelet-rich plasma³⁴ and skin grafting. No complications associated with ESWT were identified in the present study, and no contraindications were reported in a study¹⁴ involving 208 human patients.

- a. Sterile, nonadherent pad, Medline Industries Inc, Mundelein, Ill.
- b. Conforming stretch bandage, McKesson Corp, Richmond, Va.
- c. Combiroll, Franklin-Williams Co, Lexington, Ky.
- d. Vetwrap, 3M Animal Care Products, Saint Paul, Minn.
- e. Elastikon, Johnson & Johnson Consumer Co Inc, Skillman, NJ.
- f. Equitron, Sanuwave Inc, Marietta, Ga.
- g. Image J, version 1.37v, National Institutes of Health, Bethesda, Md. Available at: rsweb.nih.gov/ij/. Accessed Jan 7, 2007.
- h. Antigen Retrieval Citra Solution, BioGenex Laboratories Inc, San Ramon, Calif.
- i. IGF-I (H-70)-sc-9013, TGF- β 1 (V)-sc-146, and VEGF (A-20)-sc-152, Santa Cruz Biotechnology Inc, Santa Cruz, Calif.
- j. Multi-link (HK268-UK), BioGenex Laboratories Inc, San Ramon, Calif.
- k. Peroxidase anti-rabbit IgG (H&L) made in goat (PI-1000), Vector Laboratories Inc, Burlingame, Calif.
- l. HRP-streptavidin conjugate, Zymed Laboratories, South San Francisco, Calif.
- m. Nova red substrate kit, Vector Laboratories Inc, Burlingame, Calif.
- n. JMP Statistical Software, SAS Institute Inc, Cary, NC.
- o. Mittermay R, Hartinger J, Hofmann M, et al. How many shock waves are enough? Dose-response relationship in ischemic challenged tissue (abstr), in *Proceedings*. 11th Int Cong Int Soc Med Shockwave Treat 2008;50.

References

1. Hendrickson DA. Management of superficial wounds. In: Auer JA, ed. *Equine surgery*. 3rd ed. St Louis: Saunders Elsevier Inc, 2006;288-298.
2. Stashak TS. Selected factors that affect wound healing. In: Stashak TS, ed. *Equine wound management*. Malvern, Pa: Lea & Febiger, 1991;22-24, 36-51.
3. Berry DB II, Sullins KE. Effects of topical application of antimicrobials and bandaging on healing and granulation tissue formation in wounds of the distal aspect of the limbs in horses. *Am J Vet Res* 2003;64:88-92.
4. Wilmink J, Van Weeren PR, Stolk PWT, et al. Differences in second-intention wound healing between horses and ponies: histological aspects. *Equine Vet J* 1999;31:61-67.
5. Bertone AL. Management of exuberant granulation tissue. *Vet Clin North Am Equine Pract* 1989;5:551-562.
6. Schumacher J, Brumbaugh GW, Honnas CM, et al. Kinetics of healing of grafted and nongrafted wounds on the distal portion of the forelimbs of horses. *Am J Vet Res* 1992;53:1568-1571.
7. Wilmink J, Stolk PWT, Van Weeren PR, et al. Differences in second-intention wound healing between horses and ponies: macroscopic aspects. *Equine Vet J* 1999;31:53-60.
8. Gomez JH, Schumacher J, Lauten SD, et al. Effects of 3 biological dressings on healing of cutaneous wounds on the limbs of horses. *Can J Vet Res* 2004;68:49-55.
9. Bigbie RB, Schumacher J, Swaim SF, et al. Effects of amnion and live yeast cell derivative on second-intention healing in horses. *Am J Vet Res* 1991;52:1376-1382.
10. Howard RD, Stashak TS, Baxter GM. Evaluation of occlusive dressings for management of full-thickness excisional wounds on the distal portion of the limbs of horses. *Am J Vet Res* 1993;54:2150-2154.
11. Meirer R, Kamelger FS, Piza-Katzer H. Shock wave therapy: an innovative treatment method for partial thickness burns. *Burns* 2005;31:921-922.
12. Meirer R, Kamelger FS, Huemer GM, et al. Extracorporeal shock wave may enhance skin flap survival in an animal model. *Br Assoc Plast Surg* 2005;58:53-57.
13. Wang CG, Wang FS, Yang KD. Biological mechanisms of musculoskeletal shockwaves. *International Society for Musculoskeletal Shockwave Therapy Newsletter* 2006;1:5-11.
14. Schaden W, Thiele R, Koolpl C, et al. Shock wave therapy for acute and chronic soft tissue wounds: a feasibility study. *J Surg Res* 2007;143:1-12.
15. Meirer R, Brunner A, Deibl M, et al. Shock wave therapy reduces necrotic flap zones and induces VEGF expression in animal epigastric skin flap model. *J Reconstr Microsurg* 2007;23:231-236.
16. Wang CJ, Huang HY, Pai CH. Shock wave-enhanced neovascularization at the tendon-bone junction: an experiment in dogs. *J Foot Ankle Surg* 2002;41:16-22.
17. Kersh K, McClure SR, Van Sickle D. The evaluation of extracorporeal shock wave therapy on collagenase induced superficial digital flexor tendonitis. *Vet Comp Orthop Traumatol* 2006;19:99-105.
18. Huemer GM, Meirer R, Gurnluoglu R, et al. Comparison of the effectiveness of gene therapy with transforming growth factor- β or extracorporeal shock wave therapy to reduce ischaemic necrosis in an epigastric skin flap model in rats. *Wound Repair Regen* 2005;13:262-268.
19. Meirer R, Huemer GM, Oehlbauer M, et al. Comparison of the effectiveness of gene therapy with vascular endothelial growth factor or extracorporeal shock wave therapy to reduce ischaemic necrosis in an epigastric skin flap model in rats. *Plast Reconstr Surg* 2007;60:266-271.
20. Quinn PJ, Carter ME, Markey B, et al. Bacterial pathogens: microscopy, culture and identification. In: *Clinical veterinary microbiology*. London: Mosby Year Book Europe Limited, 1994;35-67.
21. Allen WR, Gower S, Wilsher S. Immunohistochemical localization of vascular endothelial growth factor and its two receptors in the endometrium and placenta of the mare during the oestrus cycle and pregnancy. *Reprod Domest Anim* 2007;42:516-526.
22. Al-z'abi MO, Watson ED, Fraser HM. Angiogenesis and vascular endothelial growth factor expression in the equine corpus luteum. *Reproduction* 2003;125:259-270.

23. Theoret CL, Barber SM, Moyana TN, et al. Expression of transforming growth factor $\beta 1$, $\beta 3$, and basic fibroblast growth factor in full thickness skin wounds of equine limbs and thorax. *Vet Surg* 2001;30:269–277.
24. Theoret CL. The pathophysiology of wound repair. *Vet Clin North Am Equine Pract* 2005;21:1–13.
25. Park JK, Cui Y, Kim MK, et al. Effects of extracorporeal shock wave lithotripsy on plasma levels of nitric oxide and cyclic nucleotides in human subjects. *J Urol* 2002;168:38–42.
26. Wang FS, Wang CJ, Sheen-Chen SM, et al. Superoxide mediates shock wave induction of ERK-dependent osteogenic transcription factor (CBFA1) and mesenchymal cell differentiation toward osteoprogenitors. *J Biol Chem* 2002;277:10931–10937.
27. Theoret CL, Barber SM, Moyana TN, et al. Preliminary observations on expression of transforming growth factors $\beta 1$ and $\beta 3$ in equine full-thickness skin wounds healing normally or with exuberant granulation tissue. *Vet Surg* 2002;31:266–273.
28. Barber SM. Second intention wound healing in the horse: the effect of bandages and topical corticosteroids, in *Proceedings. 35th Annu Meet Am Assoc Equine Pract* 1989;107–116.
29. McClure SR, Vansickle D, Evans R, et al. The effects of extracorporeal shock-wave therapy on the ultrasonographic and histologic appearance of collagenase-induced equine forelimb suspensory ligament desmitis. *Ultrasound Med Biol* 2004;30:461–467.
30. Caminoto EH, Alves AL, Amorim RL, et al. Ultrastructural and immunocytochemical evaluation of the effects of extracorporeal shock wave treatment in the hind limbs of horses with experimentally induced suspensory ligament desmitis. *Am J Vet Res* 2005;66:892–896.
31. Howard RD, Stashak TS, Baxter GM. Evaluation of occlusive dressings for management of full-thickness excisional wounds on the distal portion of the limbs of horses. *Am J Vet Res* 1993;54:2150–2154.
32. Moens Y, Verschooten F, De Moor A, et al. Bone sequestration as a consequence of limb wounds in the horse. *Vet Radiol* 1980;21:40–44.
33. Gerdemeyer L, von Eiff C, Horn C, et al. Antibacterial effects of extracorporeal shock waves. *Ultrasound Med Biol* 2005;31:115–119.
34. Carter CA, Jolly DG, Worden CE, et al. Platelet-rich plasma gel promotes differentiation and regeneration during equine wound healing. *Exp Mol Pathol* 2003;74:244–255.



Selected abstract for JAVMA readers from the *American Journal of Veterinary Research*

Comparison of two fecal egg recovery techniques and larval culture for cyathostomins in horses

Thomas R. Bello and Tammy M. Allen

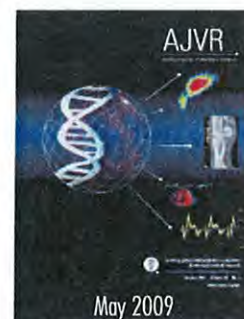
Objective—To compare the McMaster and centrifugal flotation techniques and larval culture for recovery of cyathostomin (small strongyle) eggs from the feces of horses.

Sample Population—Fecal samples from 101 horses.

Procedures—In experiment I, homogenized fresh feces from a single horse were randomly subsampled by use of each technique for 10 replicates. In experiment II, samples from 43 horses that had no anthelmintic treatment were analyzed by use of McMaster, centrifugal flotation, and larval culture techniques. In experiment III, 57 horses were treated with an anthelmintic by owners, and fecal samples were analyzed as for experiment II.

Results—In experiment I, use of the McMaster technique recovered 72% of the eggs obtained by use of centrifugal flotation from paired subsamples. In experiment II, use of the McMaster technique recovered 81% of the eggs obtained by use of centrifugal flotation. Only cyathostomins resulted from individual larval cultures. In experiment III, 24 samples had negative results for all 3 tests, 18 samples had positive results only with larval cultures, and 15 samples had positive results of centrifugal flotation (only 5 of which had positive results via the McMaster technique).

Conclusions and Clinical Relevance—Centrifugal flotation consistently was superior to the McMaster technique, especially at low fecal egg numbers. The combination of centrifugal flotation and larval culture may provide the best accuracy for evaluation of anthelmintic efficacy. (*Am J Vet Res* 2009;70:571–573)



See the midmonth issues
of JAVMA
for the expanded
table of contents
for the AJVR
or log on to
avmajournals.avma.org
for access
to all the abstracts.