

# Qualitative Evaluation of ESWT for Treatment of Cauda Equina Syndrome in Dogs and Cats

Young Joo Kim, DVM, MS, Linda Jenkins, DVM, and Edward B. Leeds, DVM, DACVS

Surgical Group for Animals, Torrance, California

**Objective** – To evaluate the clinical outcome after extracorporeal shock wave therapy (ESWT) in dogs affected by cauda equine syndrome (CES) and to report our early experience with ESWT.

**Study Design**-Retrospective Review.

**Animals**- 38 dogs and 2 cats diagnosed with CES.

**Methods**- All patients were sedated for ESWT. 1,000 shock waves were delivered over the lumbosacral area, using the probe with a focal pressure depth of 5mm or 20mm, 240 pulses per minute and an energy flux density of 0.14mJ/mm<sup>2</sup> or 0.15mJ/mm<sup>2</sup>. The treatment was repeated in three weeks if the patient regressed on recheck. The patients' responses were evaluated by the authors. The owners were required to complete pre-treatment and post-treatment questionnaires, specific to pain, stiffness, performance, and comfort level of their pets at the respective visits and through a phone survey.

**Results**- The 53 (89.8%) out of 59 animals responded to ESWT on clinician's subjective evaluation. The average owner's satisfaction score regarding ESWT was 5.75±1.86 (82.1%) out of 7. Most patients showed significant improvement from immediate after to within one week after ESWT. The median duration of ESWT effect was 13.6months (0-23 months). Five dogs and one cat out of 40 patients (15.6%) received ESWT twice. One dog (2.5%) received three times. Thirty five out of 40 clients (87.5%) would use ESWT again if needed. No adverse treatment-related effects were observed in any patient.

**Conclusion**- ESWT provides an effective method of relieving pain associated with CES in dogs and cats. ESWT may replace or enhance the chemical analgesics and delay or eliminate the need for surgical intervention.

**Clinical Relavance**- ESWT can be used to provide non-surgical treatment for CES in dogs and cats.

## Introduction

Cauda equina syndrome has been well described in both dogs and humans (Indrieri 1988; Spector, Madigan et al. 2008). Clinical signs are associated with physical compression of the cauda equina, which is the terminal part of the spinal cord, and nerve roots caused by lumbosacral instability with or without an intervertebral disc herniation (Ramirez and Thrall 1998).

Diagnosis of cauda equina syndrome is made by integrating the patient's history, clinical signs, radiographs, and when possible, advanced diagnostic imaging findings. Cauda equina syndrome is more common in large breed dogs, occurring more commonly in male dogs with the German Shepherd Dog being the most commonly affected. Cauda equina syndrome has been seen in almost all breeds including Great Danes, Labrador Retrievers, Airedales, Terriers, and Boxers (Sjostrom 2003; Spector, Madigan et al. 2008). It is also found in small dogs and cats.

Common clinical signs include lumbosacral pain, hyperesthesia with or without hyperpathia over the lower lumbar spinal region, reluctance to sit or jump, pelvic limb lameness, inappetance, personality changes, flaccid tail and sensory and/or motor neural dysfunction causing bilateral or unilateral paraparesis with prominent muscle atrophy (Sjostrom 2003). In severely affected patients, urinary or fecal incontinence can be observed (Todd 2005; Cariou, Stork et al. 2008; Spector, Madigan et al. 2008).

Lumbosacral (LS) disease can have debilitating effects on our canine and occasionally our feline patients. When conservative management fails, dorsal decompression has been described to surgically manage the dorsal lumbosacral stenosis. Surgical **procedures include** dorsal laminectomy, intervertebral disc fenestration, foraminal decompression and spinal stabilization (De Risio, JAVMA 2001). **Epidural infiltration with methylprednisone acetate has been reported with reasonable success (Janssens, VCOT 2009)**

However, the current treatment options are often less than satisfactory in alleviating pain and improving quality of life for these patients. ESWT has shown promise in treating the symptoms of LS disease. Extracorporeal shock wave technology (ESWT) is a technology that has been used for years in human and equine medicine and is more recently making a transition into small animal veterinary medicine.

Shock waves are single pulsed acoustic or sonic waves that dissipate mechanical energy at the interface of substances with different acoustic impedance. While it is somewhat new to small animal veterinary medicine it has a long history of use in equine and human medicine. Extracorporeal shock wave therapy (ESWT) has been used for the disintegration of urinary calculi since 1970's (Fuchs & Patel, 1996). Subsequent investigations have evaluated ESWT for the treatment of various musculoskeletal disorders in both humans and animal species (Buchbinder, 2006; Haupt, 1997; McClure, 2004; Schaden, 2001; Wang, 2005).

High energy ESWT is FDA-approved for the treatment of plantar fasciitis and lateral epicondylitis for human use and ESWT is often the primary treatment of choice for musculotendinous injuries in sporting horses. A shock wave is approximately 1000 times the pressure magnitude of an ultrasound wave and deposits energy at a controlled focal volume within the body. The mechanical energy transferred to tissue following an ESWT treatment causes various biological responses at the cellular level including the regulation of cytokines and growth factors leading to decreased inflammation, neovascularization and cellular proliferation.(Wang, 2002, 2003 & 2005). ESWT has also been demonstrated to speed healing and increase quality of healing in soft tissue and bone, protect chondrocytes, disintegrate calcifications, and recruiting stem cells to the treatment site.(Moretti, BMC 2008); (Gerdesmeyer, JAMA 2003); Schaden, Clin Ortho 2001; Wang, J bone Joint Surg Am 2005; Aicher, Cell Circulation 2006). Current canine clinical studies are underway for the treatment of elbow OA and shoulder injuries (Danova, 2003).

How ESWT symptomatically improves musculoskeletal conditions is not yet clearly understood. Antinociceptive effect has been proposed by blocking activation of nociceptors in the skin and deep structures that cause pain on activation. Hyperstimulation analgesia, where overstimulation of nerve fibers results an immediate analgesic effect, has been also suggested (Rompe JD, et al. J bone Joint Surg Br. 1996; Melzack R. 1975). **It was shown that ESWT quickly increase neuronal nitric oxide synthase (nNOS) activity and basal nitric oxide (NO) in the rat glioma cell, which suggested a molecular mechanism of the anti-inflammatory action of ESWT (Ciampa, et al. 2005). Clinically, an immediate vasodilatation was observed and an enhancement of angiogenesis around the ESWT treated area was found (Mariotto, et al. 2005)**

The purpose of this study was to evaluate ESWT as a non-invasive therapy for cauda equina syndrome in small animals. It was hypothesized that ESWT can improve the negative behavioral and performance symptoms that often result from the associated pain of LS disease. Therefore this client survey trial was conducted with the primary objective of obtaining feedback and evaluating the potential quality of life improvement following LS disease management with ESWT. The secondary purpose was to evaluate the clients' overall satisfaction with ESWT treatments to better evaluate the potential for incorporating ESWT as the first line treatment for LS disease in a specialized surgical practice.

## **Materials and method**

The medical records of patients with documented cauda equina syndrome treated with ESWT between **March 2008 and February 2010** at Surgical Group for Animals were reviewed. Only cases that had **clinical signs and** radiographic evidences of caudal equina syndrome were included.

The duration of clinical symptoms before ESWT was not accurately known for most cases and so was not used as part of the analysis. All neurological examinations were carried out by the same board certified surgeon, [EL]. The diagnoses of cauda equina syndrome were made by demonstrating pain or discomfort of the lower spine, and radiographic changes, such as lumbosacral spondylosis and/or dynamic angle changes between the 7<sup>th</sup> lumbar vertebra and sacrum. Pain was evaluated by historical attributes like yelping, scratching behavior and /or obvious discomfort or avoidance of being touched over the lower spine together with clinical findings like spinal hyperesthesia or reluctance to jump or stand upright on the rear legs.

### **Extracorporeal shock wave treatment**

Dogs and cats were sedated with a combination of ketamine at 25mg/kg, diazepam at 0.25mg/kg, and atropine at 0.04mg/kg administered intravenously, or a combination of medetomidine at 0.01mg/kg, butorphanol at 0.2mg/kg and atropine at 0.04mg/kg. The patients were then treated with the VersaTron 4 Paws (Pulse Veterinary Technologies, LLC, Alpharetta GA) ESWT device. The lumbosacral area was clipped and cleaned with 70% isopropyl alcohol. Conducting gel was applied and 1,000 shock waves were delivered over the lumbosacral area, using the probe with a focal pressure depth of 5mm or 20mm, 240 pulses per minute and an energy flux density of 0.14mJ/mm<sup>2</sup> or 0.15mJ/mm<sup>2</sup>. All patients were sedated for approximately 5 minutes for ESWT and discharged approximately one hour after the treatment. Owners were educated on

the risks and benefits associated with ESWT including the potential for increased pain for up to 3 days following the treatment. The treatment was repeated in three weeks if the patient regressed on recheck. After treatment, the dogs were kept on a controlled leash exercise for a week, and then allowed back to normal activity. Cats were kept cage or crate confined for a week before being allowed back into their normal environment.

### Clinician's evaluation

All treated patients were reevaluated at one and three weeks after ESWT for signs of lameness, pain on palpation of the lumbosacral spine, extension of one or both hind limbs and general attitude. Interpretation of these clinical signs was subjectively evaluated by two clinicians (EBL or YK) and the outcome was recorded as responsive or non-responsive.

### Client Questionnaire

Upon agreeing to the treatment, the clients were required to complete pre-treatment and post-treatment questionnaires specific to pain, stiffness, physical task performance, and comfort level at the respective visits and through a phone survey between March 2008 and February 2010. For each question, the owners documented their observed signs of the pain on the pet's ability to perform a specific task. The patients were graded on a 1-7 scale. A score of '1' means that the symptoms are most severe and patients are unable to perform specific task while a score of '7' means that no symptoms exist and patients are completely normal and healthy.

In addition, owners were asked about general impressions of the shock wave treatment, such as how long until the client saw an effect, how long the effect lasted, their opinion of ESWT compared to other treatments, overall satisfaction with ESWT and their willingness to use the treatment again under similar circumstances.

### Data analysis

The pre-treatment data was compared to the data from the final visit or phone survey. If either the before or after question was not answered by the owner, the patient was not included in the calculation for that specific answer but was included in calculations for all other answers for which a before and after observation was completed. In order to compare differences between before and after treatment, an ANOVA Single Factor analysis was used. Data were considered significant at  $p < 0.05$ .

## Results

### Clinician's subjective evaluation

One thirty five small animals were treated with ESWT from March 2008 to October 2010. These included patients treated at multiple treatment sites or had surgery in conjunction with ESWT. All patients treated at multiple sites or in conjunction with a surgical procedure [i.e. TPLO] were eliminated from the study. Thirty eight dogs and two cats were included in this study. The Labrador Retrievers were predominantly presented breed (7?), followed by German Shepherd Dogs (2?) and their mix (4?), Golden Retrievers (3?), Pit Bull Terriers (2?). The mean age was  $3.6 \pm 3.59$  years (range 1.4-13years) and the mean weight was  $33.2 \pm 16.6$  kg (5.1-78.1kg). The feline group included a 12 year old spayed female and a 1 year old neutered male,

who weighed 6.5kg and 4.4kg, respectively. Both cats were Russian Blue. Thirty four dogs and 2 cats out of 40 (90%) patients that were treated with ESWT improved on clinician's subjective evaluation at recheck visits. Five dogs did not show noticeable improvement. One dog became worse than before ESWT (Fig. 1). No adverse treatment-related effects were observed in any patient.

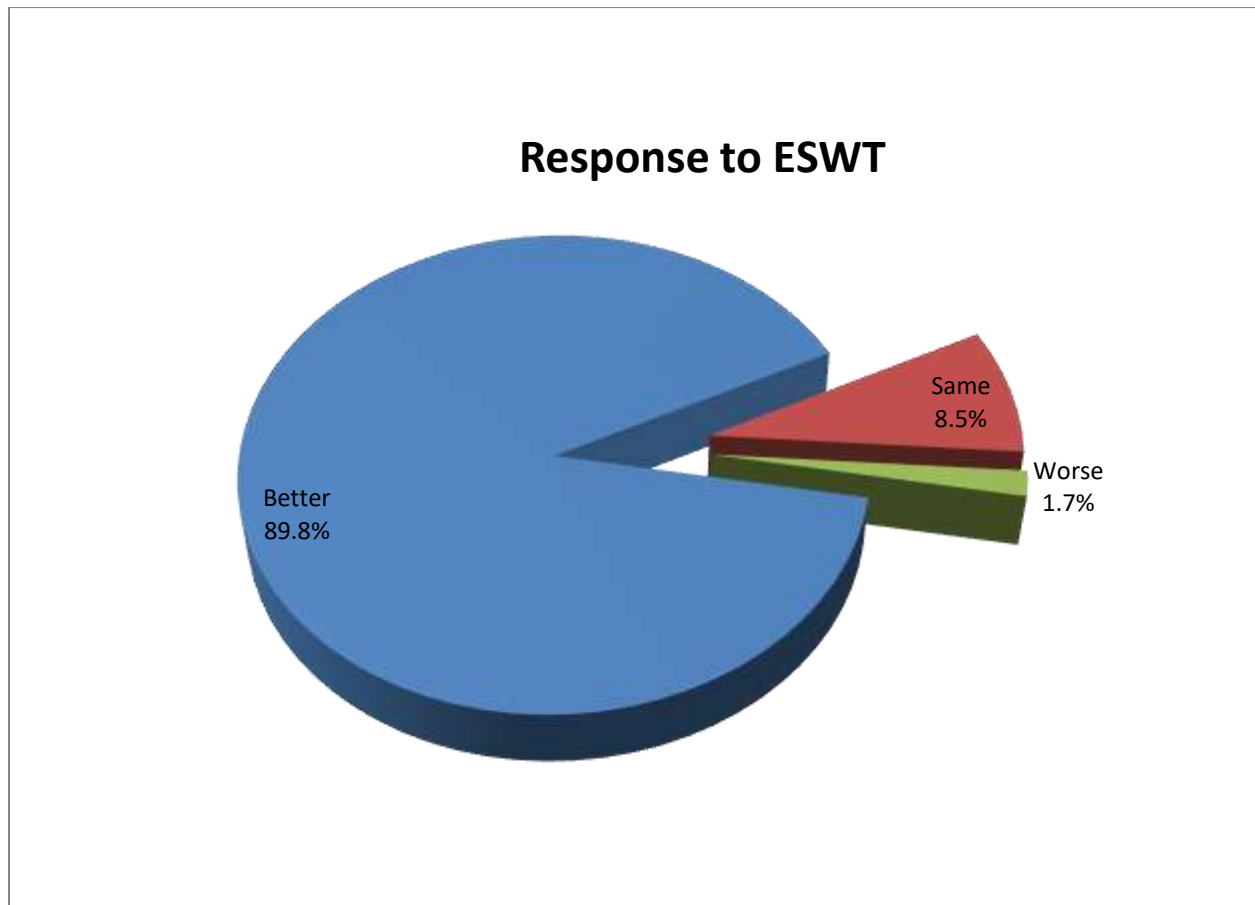


Figure 1. Patient's response to ESWT based on clinician's subjective evaluation. 89.% (53 out of 59 patients improved on recheck examination after they were treated with ESWT. Only one dog became worse ESWT.

### Client Questionnaire

One hundred small animals were treated with ESWT from Mar. 2008 to Feb. 2010. Thirty eight dogs and two cats were included in the survey. The canine group consisted of twenty two neutered males, three intact males, and ten spayed females. The Labrador Retrievers were predominantly presented breed (7), followed by German Shepherd Dog (2) and mix (4), Golden Retrievers (3), Pit Bull Terrier (2). The mean age was  $3.6 \pm 3.59$  years (range 1.4-13years) and the mean weight was  $33.2 \pm 16.6$  kg (5.1-78.1kg). The feline group included a 12 year old spayed

female and a 1 year old neutered male, who weighed 6.5kg and 4.4kg, respectively. Both cats were Russian Blue.

Most patients showed improvement from immediate after to within one week after ESWT. The median duration of ESWT effect was 13.6months (0-23 months). Five dogs and one cat out of 40 patients (15.6%) received ESWT twice. One dog (2.5%) received three times.

Prior to treatment, the most problematic symptoms reported by owners were that their animals showed a high degree of aversion to getting up and down from sitting or lying positions, not wanting to play, reluctance to climb stairs, exhibiting morning stiffness, reluctance to jump up and down and in general seeming unhappy and uncomfortable. Fig 1. provides average ratings for the degree of symptoms reported by owners of the 40 patients (1 = abnormal – unable to perform the delegated tasks and 7 = completely normal).

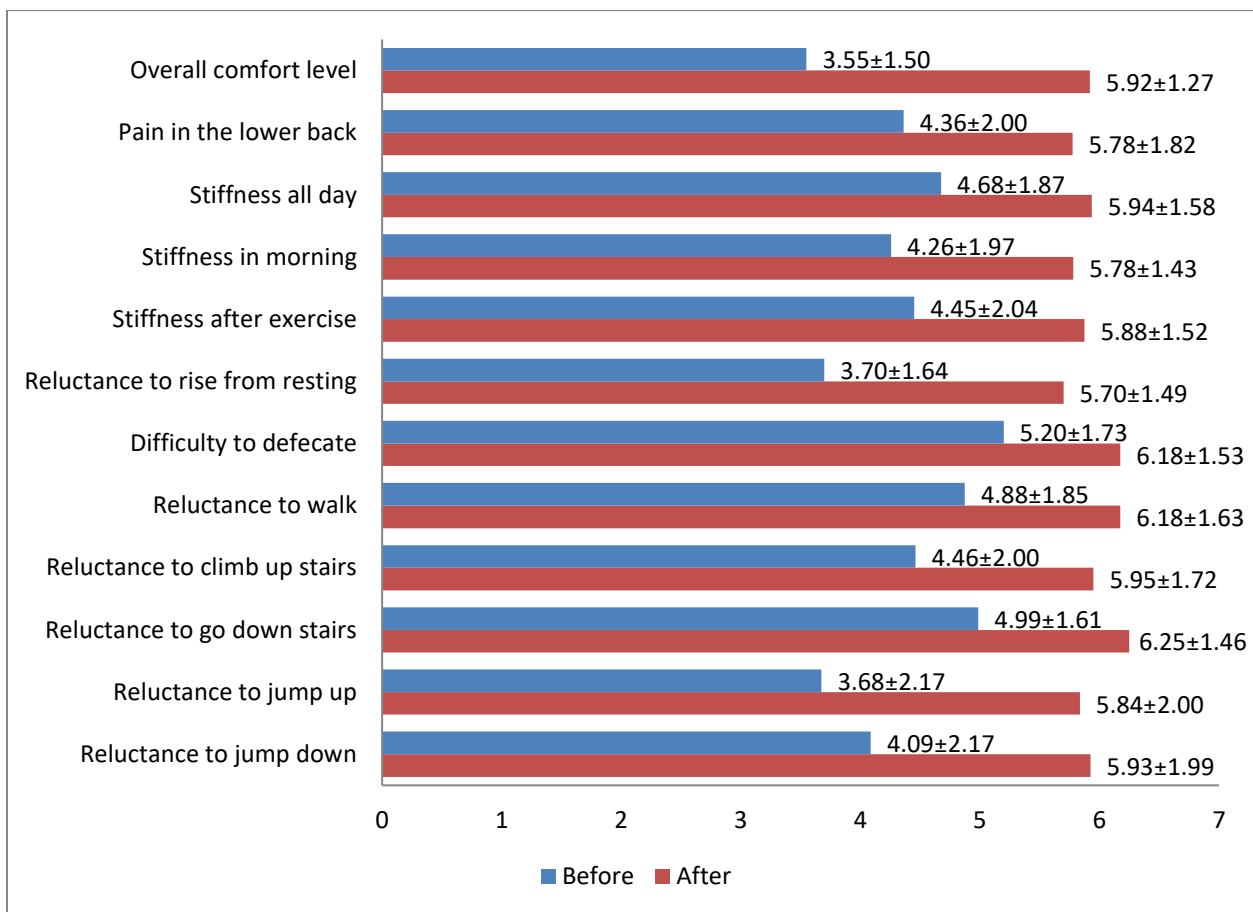


Figure 2. Subjective evaluation (rating score ± SD) by the owners before and after ESWT. ratings of patient's behavior and performance by owner before and after administration of ESWT. 1 = most severe/ unable and 7 = completely normal. There were significant improvements between before and after ESWT ( $p < 0.01$ ).

In all questions, patients showed clinically significant improvement ( $p < 0.01$ ). Patients appeared to be less painful and more comfortable. All patients were able to perform daily physical activity

better. Owners reported the greatest improvement in getting up and down, in which post treatment score was 2 points higher. At the time of the follow-up survey, 28 out of 40 patients (70%) were still seeing sustained improvement. Following treatment, owners reported that their animals were significantly more comfortable ( $p < 0.001$ ). Thirty out of 35 (86%) of owners who responded to the question regarding duration of ESWT reported results lasting greater than 3 months. Twenty eight of 35 (80%) were reported lasting greater than 6 months (Fig. 3).

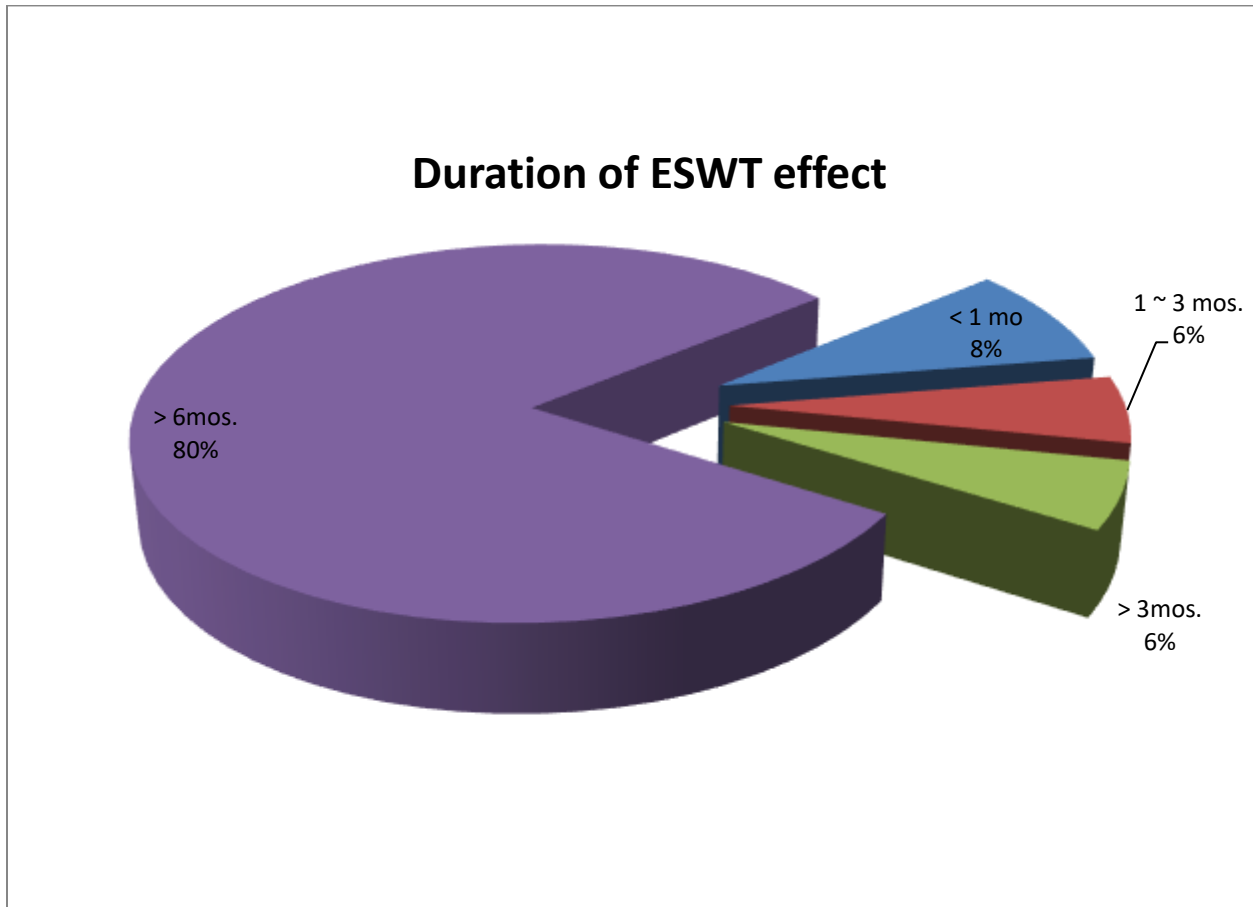


Figure 3. Duration of ESWT effect. In 86% of patients, owners reported ESWT effects lasting longer than 3 months. 80% of patients lasted longer than 6 months per owners.

Of the 36 clients who responded as to how they would grade the success of the shock wave treatment in comparison to other treatment modalities, 29 (81%) reported ESWT to be better than other treatments, 3 (8%) reported the results to be the same. 4 (11%) reported ESWT to be less successful than other forms of treatment including NSAIDs and acupuncture (Fig. 4)

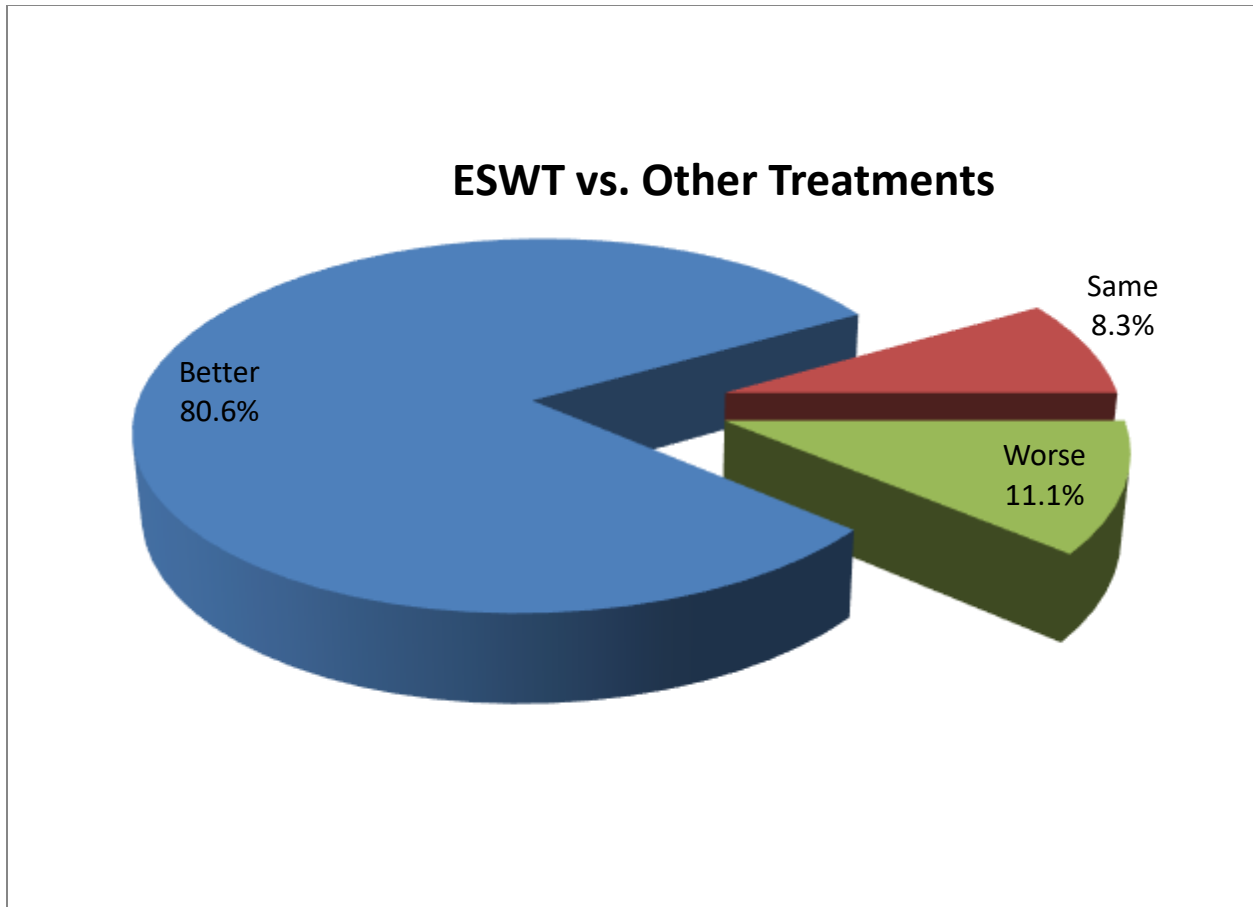


Fig. 4. **Owner's** perception of success of ESWT in comparison to other treatment modalities. 80.6% of owners reported ESWT to be better. 3% reported the results to be same, and 11% reported ESWT to be less successful than other treatments.

Of the 40 respondents, the average **satisfaction score regarding ESWT was  $5.75 \pm 1.86$  (82.1%)**. **Thirty five out of 40 clients (87.5%)** would use ESWT again if needed.

### Discussion

**CES** is a common problem without a simple standard medical treatment. For patients who are experiencing enough pain to affect their quality of life but who are not experiencing neurological symptoms, the risk and cost of surgery may outweigh the benefits. A non-invasive approach to alleviating the pain and decreased function associated with CES was needed for this patient population.

The epidural infiltration of anti-inflammatory drugs has been used in human as a first treatment choice rather than a surgery with varying success rates between 50 and 90% (Postacchini, 1996). The use of epidural infiltration in dogs with lumbosacral degenerative stenosis is a safe and well accepted treatment that seems to achieve clinical results comparable to those of decompressive



surgery (Janssens, 2009). However, the procedure requires skilled surgical techniques and also a fluoroscopy, which is not readily available to general practice.

Previous studies have demonstrated that ESWT causes a biological response in the body and stimulates repair at the cellular level in addition to decreasing inflammation, suggesting that the technology would be beneficial in treating CES. Studies have shown that degenerative disc disease involves high levels of TNF-alpha and IL-10.(Holms, Vet Pathol. 2009) ESWT has been demonstrated to reduce levels of TNF alpha and IL-10 (Moretti, 2008).

The safety profile of the technology also makes it appealing. When used correctly with the proper diagnosis, side effects are minimal to none (Gerdesmeyer, 2003; Schaden, 2001). The technology has been approved by the FDA for human use and is safely used in equine medicine to treat various back conditions including spondylosis, osteoarthritis, and dorsal spinous process impingement. A study on rabbits demonstrated morphologically and microscopically insignificant neuronal loss in comparison to the control group when 2000 impulses were delivered at low dose (0.18mJ/mm<sup>2</sup>) shockwave energy level, which is higher than the treatment protocol (0.14mJ/mm<sup>2</sup> or 0/15mJ/mm<sup>2</sup>) of this study and were applied directly to the spinal cord at a laminectomy (Lee, 2007).

In this study, 51 dogs and 2 cats out of 59 (89.8%) patients that were treated with ESWT improved on clinician's subjective evaluation. No side effect related to ESWT was reported in any patient during the treatment of 59 cases. Duration of ESWT was long lasting in most cases. The effect of ESWT lasted longer than 60 months in 80% of treated animals. Compared to traditional medical management, 81% of owners in this study reported ESWT to be better without side effects.

Only one dog did not improve and gradually got worse after ESWT was performed. From the initial trials, it was noticed that patients who had already developed neurologic deficits did not respond to ESWT, and no patients who showed neurologic deficits were included in this study. The dog that gradually became worse may have already developed some neurologic deficits even though it was not obvious.

Investigational use of ESWT for treatment of CES proved to be beneficial. ESWT proved to be effective in relieving pain and performance challenges associated with lumbosacral diseases and restrictions on mobility. Significant differences in before and after ESWT were observed on clinician's evaluation and owner's perception, which reported significant improvements. The cost of this treatment was significantly lower than associated costs of surgery and recovery. With 87.5% of the clients reporting that they would use the treatment again, it can be stated that they were satisfied with the results. Client satisfaction with not only the results but the perceived value of the treatment modality is extremely important to practice sustainability.

Advanced diagnostic imaging would have been very useful to make definitive diagnosis of cauda equina syndrome (Ramirez and Thrall, 1998). However, the availability and cost of these modalities limited their use for our clinical cases. Advanced imaging, such as MRI, followed by kinetic and kinematic gait analyses would have provided objective data, but it was not possible in this clinical setting.

Due to the retrospective nature of the study and the subtleness of the disease, owner assessment was deemed to be most appropriate and useful. **Owner questionnaires have been combined with clinician's observation** for evaluating the effectiveness of ESWT. **While clinician's observation and owner perceptions were highly subjective, they allowed preliminary conclusion to be drawn on the usefulness of ESWT.** Obviously, further documentation was needed to objectively assess its positive effects on animals in pain and discomfort. In summary, this **retrospective** study provides positive outcome to support the use of ESWT for treating CES.

## **Conclusion**

It is recommended that ESWT be considered as a first-line treatment option for moderate, non-neurological LS disease. Client reported improvement, in some cases significant improvement, in various behavioral and performance related symptoms of LS disease following treatment with focused ESWT. In addition, the clients questioned for the purpose of this study reported extremely high rates of satisfaction with the treatment outcomes.

## References

- Aicher A et al. Low-Energy Shock Wave for Enhancing Recruitment of Endothelial Progenitor Cells. *Circulation*. 2006;114:2823-2830.
- Buchbinder, R., S. E. Green, et al. (2006). "Systematic review of the efficacy and safety of shock wave therapy for lateral elbow pain." *J Rheumatol* **33**(7): 1351-63.
- Cariou, M. P., C. K. Stork, et al. (2008). "Cauda equina syndrome treated by lumbosacral stabilisation in a cat." *Vet Comp Orthop Traumatol* **21**(5): 462-6.
- Caminoto EH, Alves AI, Amorim RL, Thomassian A, Hussni CA, Nicoletti JL. Ultrastructural and immunocytochemical evaluation of the effects of extracorporeal shock wave treatment in the hind limbs of horses with experimentally induced suspensory ligament desmitis.
- Ciampa, AR, de Prati, AC, Amelio, E, Cavalieri, E, Persichini, T, Colasanti M, Musci, G, Marlinghaus, E, Suzuki, H, and Mariottto, S. Nitric oxide mediates anti-inflammatory action of extracorporeal shock waves. *Federation of European Biochemical Societies Letters* 579(2005): 6389-6845.
- Dahlberg, J., G. Fitch, et al. (2005). "The evaluation of extracorporeal shock wave therapy in naturally occurring osteoarthritis of the stifle joint in dogs." *Vet Comp Orthop Traumatol* **18**(3): 147-52.
- Danova NA, Muir P. Extracorporeal shock wave therapy for supraspinatus calcifying tendinopathy in two dogs. *Vet Res*. 2003; 152: 208-209
- De Risio L, Sharp NJ, OldbyNJ et al. Predictors of outcome after dorsal decompressive laminectomy for degenerative lumb osacral stenosis in dogs: 69 cases (1987-1997). *J Am Vet Med Assoc* 2001; 219-:624-628
- Gerdesmeyer, L. Extracorporeal Shock Wave Therapy for the Treatment of Chronic Calcifying Tendonitis of the Rotator Cuff. *JAMA*. 2003;290:2573-2580.
- Holm S, et al. Pro-inflammatory, Pleiotropic and Anti-inflammatory TNF- $\alpha$ , IL-6 and IL-10 in Experimental Porcine Intervertebral Disc Degeneration. *Vet Pathol*. 2009 Jul 15.
- Haupt G. Use of extracorporeal shock waves in the treatment of pseudoarthrosis, tendinopathy, and other orthopedic diseases. *JUrol* 1997; 158:4-11
- Indrieri, R. J. (1988). "Lumbosacral sternosis and injury of the cauda equina." *Vet Clin North Am (Sm Anim Pract)* **18**: 697-710.
- Janssens, L, Beosier, Y, and Daems, R. Lumbosacral degenerative stenosis in the dog. *VCOT* 2009: 22: 486-491

Lee TC, Huang HY, Yang YL, Hung KS, Cheng CH, Chang NK, Chung YH, Hu MS, Wang CJ. Vulnerability of the spinal cord to injury from extracorporeal shock waves in rabbits. *J Clin Neurosci*. 2007;14:873-8

Mariotto, S., Cavalieri, E. Amelio, E. Ciampa, A.R., dePrati, A. Carcereri, and Marlinghaus, E., et al. (2005) Extracorporeal shock waves: from lithotripsy to anti-inflammatory action by NO Production. *Nitric Oxide* 12, 89-96.

McClure SR, Van Sickle D, White MR. "Effects of extracorporeal shock wave therapy on bone." *Vet Surg*. 2004;33(1): 40-8.

Melzack, R. Prolonged relief of pain by brief, intense transcutaneous somatic stimulation. *Pain*. 1975; 1: 357-73

Moretti B, et al. Extracorporeal shock waves down-regulate the expression of interleukin-10 and tumor necrosis factor-alpha in osteoarthritic chondrocytes. *BMC Musculoskelet Disord*. 2008;9:16.

Postacchini f. Spine update. Results of surgery compared with conservative management for lumbar disc herniations. *Spine*. 1996; 1383-1387.

Ramirez, O., 3rd and D. E. Thrall (1998). "A review of imaging techniques for canine cauda equina syndrome." *Vet Radiol Ultrasound* 39(4): 283-96.

Rompe, J. D., et al. Analgesic effect of extracorporeal shock-wave therapy on chronic tennis elbow. *J Bone Joint Surg Br*. 1996; 78:233-7

Schaden, W., A. Fischer, et al. (2001). "Extracorporeal shock wave therapy of nonunion or delayed osseous union." *Clin Orthop Relat Res*. 2001;387:90-4.

Sjostrom, L. (2003). Lumbosacral Disorders. In: Slatter D. Textbook of small animal surgery. Textbook of Small Animal Surgery. Philadelphia, Saunders. 1: 1227-1237.

Spector, L. R., L. Madigan, et al. (2008). "Cauda equina syndrome." *J Am Acad Orthop Surg* 16(8): 471-9.

Todd, N. V. (2005). "Cauda equina syndrome: the timing of surgery probably does influence outcome." *Br J Neurosurg* 19(4): 301-6; discussion 307-8.

Wang CJ, Wang FS, et al. "Shock wave therapy induces neovascularization at the tendon-bone junction. A study in rabbits." *J Orthop Res*. 2003;21(6):984-9.

Wang CJ, Wang FS, et al. "Treatment for osteonecrosis of the femoral head: comparison of extracorporeal shock waves with core decompression and bone-grafting." *J Bone Joint Surg Am*. 2005; 87(11): 2380-7.

Wang FS, Yang KD, et al. "Extracorporeal shock wave promotes growth and differentiation of bone-marrow stromal cells towards osteoprogenitors associated with induction of TGF-beta1." J Bone Joint Surg Br. 2002;84(3):457-61.